

# Expert Opinion

1. Introduction
2. Periocular routes
3. Pharmacokinetics of periocularly administered drugs
4. Mechanisms of trans-scleral drug delivery
5. Sustained release systems for periocular delivery
6. Pharmacodynamics
7. Future challenges
8. Conclusions
9. Expert opinion

For reprint orders, please  
contact:  
[reprints@ashley-pub.com](mailto:reprints@ashley-pub.com)

Ashley Publications  
[www.ashley-pub.com](http://www.ashley-pub.com)



## Periocular routes for retinal drug delivery

Swita Raghava, Makena Hammond & Uday B Kompella<sup>†</sup>

<sup>†</sup>*Department of Pharmaceutical Sciences, University of Nebraska Medical Centre, Omaha, NE 68198-5840, USA*

Despite numerous scientific efforts, delivery of therapeutic amounts of a drug to the retina remains a challenge. This challenge is compounded if chronic therapy is desired. The inability or inefficiency of topical and systemic routes for retinal delivery of existing drugs is now widely accepted. Although the intravitreal route offers high local concentrations in the vitreous and, hence, retina, these advantages are offset by side effects, such as cataracts, endophthalmitis and retinal detachment, following repeated intravitreal injections, or intravitreal placement of sustained-release implants. As discussed in this review, periocular routes, including subconjunctival, sub-tenon, retrobulbar, peribulbar and posterior juxtascleral routes, potentially offer a more promising alternative for enhanced drug delivery to the retina compared with topical and systemic routes. Periocular routes exploit the permeability of sclera for retinal drug delivery, and they are particularly useful for administering sustained-release systems of potent drugs. This review discusses the various periocular routes with respect to their anatomical location, pharmacokinetics, safety and mechanisms of drug delivery. In the coming years, several innovations in absorption enhancement, drug delivery systems and drug administration devices are anticipated for improving retinal drug delivery via periocular routes.

**Keywords:** peribulbar, pharmacokinetics, retina, retrobulbar, subconjunctival, sub-tenon, sustained release

*Expert Opin. Drug Deliv.* (2004) 1(1):99-114

### 1. Introduction

Drug delivery to the posterior segment of the eye is useful in treating various disorders, including degenerative, vascular and proliferative disorders (Table 1). The retina is the primary target for most of these disorders. Delivery of therapeutic concentrations of drugs to the retina continues to remain a challenge for pharmaceutical scientists because of the anatomical and physiological barriers associated with this tissue [1,2]. The challenges are compounded if chronic therapy is required, as is the case with diabetic retinopathy and age-related macular degeneration. Topical instillation of drug solution into the inferior fornix of the conjunctiva is most often used for ocular administration, and this route has been successful in treating diseases afflicting the anterior segment of the eye. For topically administered medications, the cornea and conjunctiva are the primary barriers for ocular drug entry. These barriers, in conjunction with nasolacrimal drainage of administered drops, drug metabolism, protein binding, lens barrier and long diffusional path lengths, result in poor drug delivery to the retina following topical administration. Systemically administered therapeutic agents reach the retina to a limited extent due to the presence of blood–ocular barriers, which include the blood–aqueous and blood–retinal barriers. The blood–aqueous barrier is formed by the non-pigmented layer of the ciliary epithelium and the endothelium of the iris vessels. The blood–retinal barriers include the retinal pigment epithelium and the endothelium of the retinal vessels. Due to these barriers and low

**Table 1. Disorders afflicting the posterior segment of the eye.**

Classification	Examples	Target tissue
Degenerative diseases	Age-related macular degeneration, retinitis pigmentosa	Retina
Vascular diseases	Diabetic retinopathy, retinal vein or arterial occlusion, retinopathy of prematurity, age-related macular degeneration	Retina
Inflammatory diseases	Uveitis	Uveal tissues, sclera, iris, retina
Proliferative diseases	Proliferative vitreoretinopathy	Vitreous and retina
Infectious diseases	Endophthalmitis	Vitreous and/or retina
Others	Glaucoma, optic neuritis	Optic nerve

cardiac output to the retina [3], attainment of therapeutic effect in the retina requires high systemic doses, which can produce harmful side effects because most drugs intended for the eye were originally developed for systemic use [4,5].

To improve the retinal delivery of drugs, various local modes of administration, including intracameral, intravitreal and periocular routes, have been assessed. Intracameral injection refers to injection of drug solution in the anterior chamber of the eye. Up to 100 µl volume can be injected by this route. Intracameral injections are used in cataract surgery and for the management of diseases afflicting the anterior segment. This route of administration fails to deliver significant concentrations of drugs to the posterior segment [6].

Since the first report on intravitreal injections in 1944, this mode of administration has found wide clinical application for treating vitreoretinal disorders [7]. Intravitreal injections can provide high drug concentrations to the neural retina. However, bolus intravitreal injections result in high local concentrations of drugs, which can potentially cause retinal toxicity, as is the case with gentamicin [8]. In addition, repeated intravitreal injections can lead to retinal detachment [9]. The half-lives of representative drugs in the vitreous following intravitreal administration are summarised in **Table 2** [10–13]. It is noteworthy that the elimination half-lives of drugs increase with molecular weight in the vitreous. On the other hand, in the plasma, peptide and protein drugs exhibit short elimination half-lives [14]. Due to this unique vitreal clearance property, macromolecules such as vascular endothelial growth factor (VEGF) aptamer and VEGF antibody fragments are under development for intravitreal administration. However, such drugs still require repeated intravitreal administrations in treating chronic disorders, which might exacerbate the risks.

Periocular routes, which for the purpose of this article include subconjunctival, sub-tenon, retrobulbar, peribulbar and posterior juxtасcleral, offer alternative approaches for delivering drugs to the retina (**Figure 1**). If a drug is administered by these routes, it can be delivered to the sclera, choroid, retinal pigment epithelium, neural retina and vitreous, in that order, depending on source concentration and the barrier properties of these and other intermittent layers between the site of administration and the target site. As these routes are showing promise for retinal delivery of some drugs, the following discussion provides a

description of the methods of administration, pharmacokinetics, mechanisms of delivery, sustained-release systems and pharmacodynamics for periocularly administered drugs.

## 2. Periocular routes

### 2.1 Subconjunctival

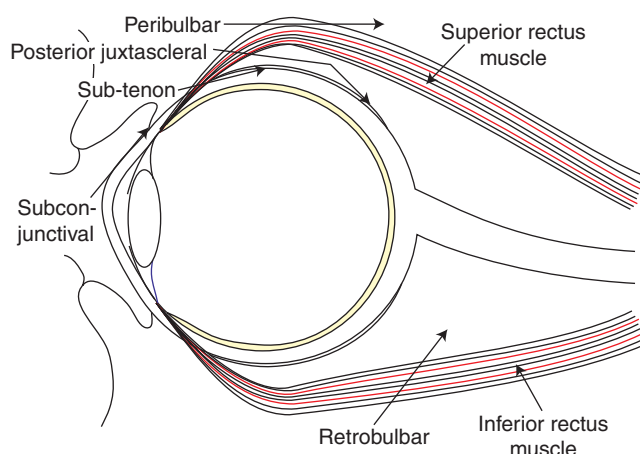
Subconjunctival injection implies injection of the drug solution underneath the conjunctiva. The conjunctiva is a thin continuous membrane lining the eye beginning from the eyelids to the corneoscleral junction. A needle of up to 25 – 30 gauge and 30 mm long, and a volume of up to 0.5 ml may be used for this particular method of administration. During injection, the bevelled edge of the needle is made to face the sclera and is slid under the bulbar conjunctiva, which is loosely attached to the sclera  $\geq 3$  mm beyond the limbus, until a fold appears [15]. This route has been previously shown to be effective in delivering drugs to both the anterior and posterior segments of the eye.

### 2.2 Sub-tenon

Although sub-tenon injections were reported as early as 1956, they were not extensively used until 1990 [16]. Sub-tenon administration usually implies injection of drugs into the tenon's capsule around the upper portion of the eye and into the belly of the superior rectus muscle [15]. The tenon's capsule is a fibrous membrane that envelops the globe from the margin of the cornea to the optic nerve [17]. The sub-tenon space is a virtual cavity bound by the tenon's capsule and the sclera, and is divided into anterior and posterior segments at the insertions of the extraocular muscles and their associated fasciae [18]. While injecting drugs, the patient is directed to look downward as the upper lid is retracted [15]. Subsequently, a 2.5 cm long, blunt-tipped cannula needle is passed into the tenon's capsule at the temporal edge of the superior rectus muscle after a surgical dissection into the sub-tenon's space is made. The injection is directed posteromedially, and up to 4 ml of drug formulation is injected around the muscle belly behind the equator [19]. Although subconjunctival haemorrhaging may be a complication, sub-tenon injection is a widely used technique for anaesthesia during ocular surgery, due to the fact that sharp needle complications can be avoided with the cannula approach. The conventional technique for

**Table 2. Vitreous humor half-lives of drugs administered intravitreally.**

Drug administered	Molecular weight	Species	Half-life (h)	Reference
ISIS 2922 (oligonucleotide)	7122.16	Rabbit	62	[10]
Octreotide acetate	1019.3	Rabbit	16	[11]
Dexamethasone	392.47	Rabbit	3.48	[12]
Ceftizoxime	405.38	Rabbit	5.7	[13]

**Figure 1. Schematic representation of periocular routes of administration.**

posterior sub-tenon injection involves the use of a sharp-tipped 26-gauge 5/8 inch needle that must be inserted up to its hub to obtain adequate placement of the drug into the posterior sub-tenon space.

### 2.3 Retrobulbar

Retrobulbar injection refers to the injection in the conical compartment within the confines of the four rectus muscles and their intermuscular septa [16]. Injection of a drug formulation is made within the muscle cone behind the globe of the eye [20]. This injection is usually performed with a blunt 25- or 27-gauge needle. Although sharp needles cause less pain due to injection, using a needle tip with less cutting ability reduces inadvertent injury to the eye [21]. The entry site for retrobulbar injection begins at the inferotemporal orbital margin with the eye in the primary gaze position, and the needle is aimed at the lower edge of the superior orbital fissure [22]. Typically, the needle is directed 45° from the sagittal plane and 10° superiorly. After insertion of ~ 3 mm beyond the posterior surface of the globe, an injection of up to 5 ml may be made. The globe is ~ 25 mm in diameter. Therefore, the needle should not be directed behind the globe until this depth has been reached from the most anterior surface of the cornea. This type of injection places the optic nerve at risk for trauma including a subarachnoid injection. To avoid optic nerve injury, the needle is kept in the temporal half of the orbit and should penetrate no further than 1.5 cm behind the globe [21].

With retrobulbar injection, higher local concentrations may be achieved for anaesthesia or akinesia of the globe during surgery, and there is little to no influence on intraocular pressure.

### 2.4 Peribulbar

Peribulbar injection was popularised in 1986 as an alternative to avoid the complications experienced with retrobulbar method [19]. Peribulbar injection indicates an injection made at the location external to the confines of the four rectus muscles and their intramuscular septa [16]. With this method, unlike the retrobulbar method, the muscle cone is never entered [20]. Peribulbar injection can be performed in two ways – that is, injection at the inferotemporal position after a slight cephaloposterior trajectory and injection at the supernoasal position just below and medial to the supratrochlear notch. Inferior injections are given at the junction of the outer third and inner two-thirds of the lower orbital rim [19]. The needle is directed away from the eye and toward the floor of the orbit, with the eye in primary gaze position. Superior injections can be given either nasally or temporally toward the roof of the orbit. However, temporal administration is preferable due to the fact that the regions encountered are less vascular. Depth of the needle is controlled by observing the needle–hub junction reaching the plane of the iris. A 25-gauge, 1.25 inch needle is used and directed just beyond the equator of the globe. It has been reported that depending on the compliance and speed of injection, up to 8 – 10 ml of anaesthetic may be given in a periconal fashion. To avoid the risk of globe perforation, care should be taken to ensure that the needle is placed away from the globe. The peribulbar route is less effective than the retrobulbar route in anesthetising the globe. However, it is a safer mode of administration.

### 2.5 Posterior juxtascleral

This is a unique delivery approach developed by Alcon Laboratories Ltd, which uses a blunt-tipped, curved cannula for delivering the drug formulation in direct contact with the outer surface of the sclera without puncturing the eyeball [23]. This delivery route is being used by Alcon to deliver a depot formulation of anecortave acetate (Retaane®), being investigated to treat age-related macular degeneration patients. This approach allows placement of the depot near and above the macula, allowing efficient and prolonged drug delivery to the macular region. For the drug administration, the patient is placed supine, the suspended medication is drawn into the

syringe, and a specially designed 56° cannula is then placed on the syringe [23]. After applying povidone-iodine 5% to the periocular skin and cul-de-sac, a lid speculum is inserted. After topical anaesthesia, to expose the sclera, a 1 – 1.5 mm incision is made in the superotemporal quadrant, midway between the superior and lateral rectus muscles, through the conjunctiva and tenon's capsule, 8 mm posterior to the limbus. When sclera is visualised, the curved portion of the cannula is inserted, keeping the cannula tip in constant direct apposition to the scleral surface. Once the cannula is fully inserted without resistance, pressure is applied along the sides and top of the cannula with a pair of sterile cotton swabs to prevent any reflux, and 0.5 ml of the medication is injected slowly. The cannula is withdrawn while maintaining gentle pressure using the cotton swabs. Following this procedure, the lid speculum is removed, topical antibiotic is applied, and the eye is patched lightly.

### 2.6 Safety of periocular injections [16-18]

As periocular routes are most widely used for ocular anaesthesia, safety information is readily available for the administration of anaesthetics by these routes. Because of the proximity of the injection site to the nerves and muscles that need paralyzing prior to surgery, retrobulbar injections are the most efficient among periocular routes in anaesthetising the globe. However, these injections are associated with the highest number of complications. The complications include retrobulbar haemorrhage, globe perforation and respiratory arrest as a result of brainstem anaesthesia, with their incidence being 1.7, 0.75 and 0.3%, respectively. Peribulbar anaesthesia is safer, with a 0.0008% incidence of globe perforations and no occurrence of retrobulbar haemorrhage or respiratory arrest. Compared with retrobulbar and peribulbar injections, which use sharp needles, the sub-tenon approach employing a cannula is emerging as a safer alternative. For this reason, the Royal Colleges of Ophthalmologists and Anaesthetists have endorsed sub-tenon block as a procedure in which an anaesthetist need not be present, if a sharp-needle block is not being employed. Swelling of conjunctiva or chemosis and subconjunctival haemorrhage are complications associated with sub-tenon injections, with an incidence rate of 39.4 and 32 – 56%, respectively.

The risks associated with retrobulbar and peribulbar injections can be further minimised through the latest technological advances such as real-time tomography reflection of sonographic images [24]. In sonography, the operator must look away from the patient in order to see the sonographic screen and, therefore, must rely on a displaced sense of hand-eye coordination. This problem can be overcome by exploring methods for viewing the sonographic image, patient, instrument, and operator's hand in one environment. It has been observed that with the use of Sonic Flashlight, the globe, optic nerve and retrobulbar space can be visualised at their expected visual locations relative to the external anatomy. Chang *et al.* [24] reported that on insertion of the needle, the

needle can be clearly seen passing the region inferior to the globe and into the retrobulbar space, while easily avoiding surrounding structures. With the same technique, the needle puncturing the globe is also clearly visualised. Sonography can potentially be employed to avoid the risks associated with other periocular injections. Unlike eye drops, the disseminated use of periocular routes for drug delivery may be limited by access to well-equipped medical care facilities, especially in the developing world.

## 3. Pharmacokinetics of periocularly administered drugs

An understanding of drug absorption, distribution and elimination (pharmacokinetics) is indispensable in identifying a therapeutic regimen and designing a delivery system [25]. However, there are very few ocular pharmacokinetic studies conducted in humans, because there is no safe way of continuously sampling intraocular tissues or fluids without causing pain or injury. Therefore, drug development for the eye relies heavily on preclinical pharmacokinetic studies. The usefulness of animal models in predicting human ocular pharmacokinetics can be improved by taking into account the anatomical and physiological dissimilarities between the eyes of various species. Ocular preclinical pharmacokinetic studies have been helpful in [25]: determining the best route of administration for entry into the eye, as well as accumulation at the site of action; validating the minimum effective concentrations in various tissues from different routes of administration; determining the elimination half-life, which can serve as a guide to the selection of dosing regimens for further study; and estimating the safety of various drugs by determining their accumulation in the relevant tissues.

In order to obtain valid results with drug delivery and pharmacokinetic studies, the investigators should establish validated assays and tissue isolation procedures. Ideally, the tissue isolation procedures should ensure lack of cross-contamination between various tissue layers, and eliminate drug diffusion between tissues post-isolation and prior to analysis. For determining drug levels in the retina, isolated neural retina is desired, as opposed to retina-choroid preparations.

### 3.1 Drug delivery to the posterior segment from eye drops

Interest is growing in determining whether a drug administered as an eye drop reaches the posterior segment of the eye to any significant levels. Although the literature is supportive of drug delivery to the posterior segment of the eye from topical drops, the concentrations achieved are a minute fraction of the concentration in the dosing solution [26]. However, if the drug is highly potent and there is appreciable drug accumulation in the target tissue, pharmacological effects may be seen in the posterior segment of the eye that can be attributed to the eye drops. A study in pigmented rabbits concluded that topical instillation of a 0.03% solution of iganidipine, a Ca<sup>2+</sup>

antagonist, delivers drug to the ipsilateral posterior retina or retrobulbar periocular space by local penetration at concentrations sufficient to act as a  $\text{Ca}^{2+}$  antagonist [27]. It was observed that 20-day instillation of iganidipine 0.03% b.i.d., but not of betaxolol (0.5%), significantly suppressed constriction of the retinal arteries in the ipsilateral eye induced by intravenous injection of endothelin-1. Intravenous injection of iganidipine at a dose of 30  $\mu\text{g/kg}$  significantly suppressed intravenous endothelin-1-induced constriction of the retinal artery to a similar degree as 20-day instillation of iganidipine 0.03% b.i.d. After a single instillation of 0.09% iganidipine, the equivalent concentration of iganidipine in the ipsilateral retrobulbar periocular space estimated from autoradiography was  $\sim 3.9 \times 10^{-8} \text{ M}$  between 15 min and 1 h after instillation, consistently higher than the levels in the untreated contralateral eyes by  $\sim 3 \times 10^{-8} \text{ M}$ .

Nepafenac, a non-steroidal anti-inflammatory agent, has been shown to prevent the mitogen-induced pan-retinal oedema following topical ocular application in rabbits [28]. Topical application of 0.5% nepafenac produced 65% reduction in retinal oedema, which correlated with 62% inhibition of blood-retinal barrier breakdown. Topical nepafenac also inhibited ocular neovascularisation in three murine models [29]. Mice treated with 0.1 or 0.5% nepafenac exhibited significantly less choroid neovascularisation and significantly less ischaemia-induced retinal neovascularisation compared with vehicle-treated mice.

A recent study indicated that insulin accumulates in the retina and optic nerve following topical application [30].

The above findings indicating the delivery of iganidipine, nepafenac and insulin are consistent with the non-corneal or conjunctival route of drug delivery reported by Ahmed and Patton [31]. Thus, it is not surprising that drugs administered next to the sclera can enter the intraocular tissues.

### 3.2 Rationale for the use of periocular routes for retinal drug delivery

Even though only a small fraction of the concentration of topically administered eye drops (estimated by Maurice at 1/1500 for lipophilic metipranolol and 1/150,000 for hydrophilic fluorescein) reaches the aqueous humor [32], several hydrophilic and lipophilic drugs are administered routinely as drops for treating glaucoma. Some of these topical drops are claimed to have effects in the posterior segment. It is fair in the authors' opinion to assume that some potent drugs will be useful in delivering therapeutic drug levels to the posterior segment of the eye when they are administered periocularly. Periocular routes, as discussed below, generally deliver greater drug levels to the posterior segment of the eye compared with the topical or systemic modes of administration. A large dilution of the dosing solution at target site [26] does not mean that the fraction delivered to the posterior segment of the eye is of a similar magnitude, because various distribution parameters lead to spontaneous dilution of the drug in different tissues. This is analogous to administrations

of low-molecular-weight drugs by the intramuscular route, wherein the peak plasma concentrations attained would be a very small fraction of the concentration of the drug in the dosage form, but the fraction absorbed could be nearly complete. The fraction of the dose absorbed into the posterior segment of the eye from the periocular routes is expected to be higher than is feasible with topical administration and generally even following systemic modes of administration. However, the actual fraction absorbed following periocular administration will be low due to drug loss into the blood, as suggested by Lee and Robinson [33,34].

Even low bioavailability of a drug should not deter a drug from development, especially if it is potent and has a good safety profile at doses required for exerting the therapeutic effect. Lessons can be learned from drugs administered by other routes. One such example is naferelin, a peptide drug with activity on the pituitary gonadal axis, which allows its use in the treatment of precocious puberty and endometriosis. This peptide is available as a nasal spray at a concentration of 2 mg/ml for the treatment of endometriosis and precocious puberty. The average peak concentration was 0.6 ng/ml in the serum following a single nasal spray of 100  $\mu\text{l}$  naferelin solution in adult women, and this was 2.2 ng/ml in children with precocious puberty following the administration of two nasal sprays [35]. Thus, there is at least 1,000,000 times dilution of the dosing solution in serum, and this dilution would be even greater at the target tissues. The estimated serum bioavailability of this drug from the nasal cavity is 2.8% in healthy female volunteers [36]. This is only one example among several commercially available drugs, in which not the target: dosage form drug concentration ratio, but the effect, becomes the driving force for drug product development. In other words, potent yet safe drug molecules will find multiple applications by the periocular routes.

### 3.3 Pioneering work in periocular pharmacokinetics

Several investigators have assessed the pharmacokinetics of periocularly administered drugs. Key contributors to this area included M Barza, J Robinson and D Maurice, among others. The following summarises some key findings in this area.

Barza, through meticulously designed studies, determined the pharmacokinetics of drugs, primarily antibiotics intended for treating intraocular infections, with the target for delivery being the vitreous [13]. He demonstrated that drugs can enter the vitreous following subconjunctival, sub-tenon and retrobulbar administrations. He also suggested that the drug entry is more localised within the eye to the region of administration with subconjunctival administration and more uniformly distributed to the intraocular tissues with retrobulbar administrations. His investigations, along with those of Maurice early on indicated that the injection of the drug subconjunctivally in the superior quadrant of the eye results in greater drug levels in the anterior segment of the eye compared with an injection in the inferior quadrant [37,38]. However, these two modes of administration did not result in any significant differences in the vitreous drug

**Table 3. Delivery of dexamethasone to the subretinal fluid following administration by various routes.**

	Subconjunctival	Peribulbar	Oral	Reference
C <sub>max</sub> (ng/ml)	359 (80.2)	82.2 (17.6) <sup>‡</sup>	12.3 (1.61) <sup>‡</sup>	[43]
T <sub>max</sub> (h)	2.45 (0.166)	3.01 (0.134) <sup>‡</sup>	5.06 (0.433) <sup>‡</sup>	
Dose (mg)*	2.5	5	7.5	
Number of patients	49	50	49	

\*Dose is expressed as the weight of dexamethasone disodium phosphate administered. <sup>‡</sup>The values in the parenthesis represent standard error.

levels. These findings can be explained on the basis that when the drug is injected in the superior quadrant, it directly drains into the tear film over the cornea, exposing greater concentrations of the drug to the cornea compared with an injection made in the inferior quadrant. The similar quantities in the vitreous may be because the pathways followed to the vitreous (penetration across sclera and systemic pathway) are similar for both modes of administration. Investigations of Wine *et al.* [39] and Maurice and Ota [37] demonstrated that the backward drainage of solution along the needle track, as well as the diffusion across the conjunctiva into the tear film, contribute to high drug levels attained in the anterior segment of the eye following subconjunctival injection. The contribution of high drug levels to the anterior segment following subconjunctival injection are unequivocal, and injections are recommended in several clinical situations [40]. However, if the same therapeutic goals can be accomplished with eye drops, the drops are preferred.

To understand the relative contribution of the drug entering the anterior chamber to the vitreous level after subconjunctival injection, Lee and Robinson [6] carried out a study in New Zealand albino rabbits. <sup>14</sup>C-mannitol was injected subconjunctivally, and <sup>14</sup>C-mannitol and <sup>14</sup>C-inulin were injected intracamerally. The aqueous and vitreous levels were determined at selected time points. The authors found that movement of the drug from the aqueous chamber backwards to the vitreous after subconjunctival injection contributes minimally to drug levels in the vitreous. Although a minute quantity of the drug can enter the vitreous via this pathway, this pathway can be practically neglected as a potential pathway for drug delivery to the posterior segment of the eye after subconjunctival injection. Although fraction absorbed has been estimated to be low for subconjunctivally administered drugs [33], systematic studies need to be performed to quantify the fraction of the dose absorbed into the tissues of the posterior segment. Whereas such an assessment would be straightforward in the vitreous, similar measures in the retina would be more difficult.

Based on the work of Barza, which demonstrated that subconjunctival injections result in less than the desired concentrations of antibiotics in the vitreous, sufficient caution should be exercised in choosing the type of drug to be delivered to the posterior segment via periocular routes, especially if the vitreous is the intended target. In the case of cephalosporins, even though 3 – 13 mg/l concentrations were attained in the vitreous following single subconjunctival

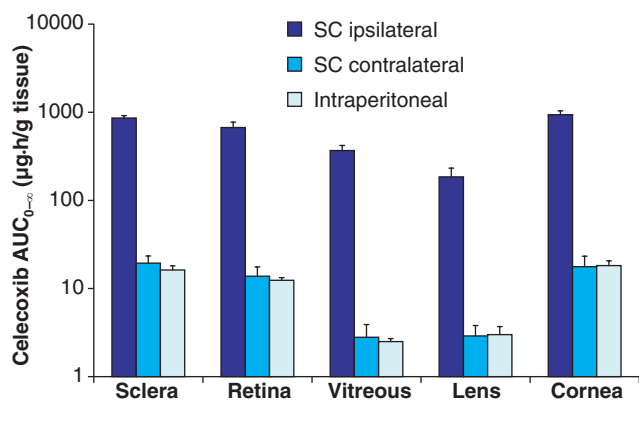
injection in rabbits, they were deemed to be insufficient [13]. It appears that more potent molecules should be chosen for this mode of administration.

In summary, pharmacokinetic literature comparing the various periocular routes for their effectiveness in delivering drugs to the tissues of the posterior segment is sparse. Systematic studies have been performed for antibiotics. Subconjunctivally administered drugs can leak back along the needle track or diffuse across conjunctiva to reach the tissues of the anterior segment. A small fraction of the dose administered periocularly reaches the tissues of the posterior segment including the vitreous. The levels achieved in the vitreous may not be effective for antibiotics such as cephalosporins assessed by Barza. Thus, more potent drugs should be chosen if vitreal drug delivery is intended. In addition, the drug loss to the blood circulation should be minimised by employing innovative approaches in order to enhance the fraction of the dose absorbed into the posterior segment. The various periocular routes are likely to result in different pharmacokinetic profiles for a given drug. Although Barza and group addressed this to an extent for antibiotics, it deserves renewed attention due to the availability of superior analytical techniques.

### 3.4 Periocular routes deliver drug to the vitreous in humans

From their study to determine the dexamethasone concentration in aqueous, vitreous and serum of phakic patients after a subconjunctival injection of dexamethasone disodium phosphate, Weijtens *et al.* [41] concluded that subconjunctival injection is more effective compared with peribulbar and oral administrations for delivering dexamethasone into the posterior segment of the eye. These levels are higher than those obtained in the vitreous following topical instillation in humans [42]. The authors also observed considerable systemic absorption following subconjunctival injection. The dose of dexamethasone injected subconjunctivally was 2.5 mg. The estimated maximum dexamethasone concentration was 858 ng/ml at 2.5 h after injection in the aqueous, and 72.5 ng/ml at 3 h in the vitreous. In serum, a mean maximum concentration of 32.4 ng/ml was measured at ~ 30 min after injection.

A comparison of subretinal fluid concentration of dexamethasone attained following subconjunctival, peribulbar and oral administration of dexamethasone disodium phosphate to patients with a rhegmatogenous retinal



**Figure 2. Local delivery is responsible for higher ocular tissue availability of celecoxib following subconjunctival administration.** Celecoxib suspension was administered SC to one eye at a dose of 3 mg/rat, and drug levels were estimated in the tissues from the dosed (ipsilateral) eye as well as the undosed (contralateral) eye. In addition, drug suspension was administered intraperitoneally at a dose of 3 mg and the drug levels were estimated in various ocular tissues. The area under the tissue concentration versus time plot ( $AUC_{0-\infty}$ ) is expressed as mean  $\pm$  s.d. for  $n = 4$  for subconjunctival injection and  $n = 6$  for intraperitoneal injection [44].

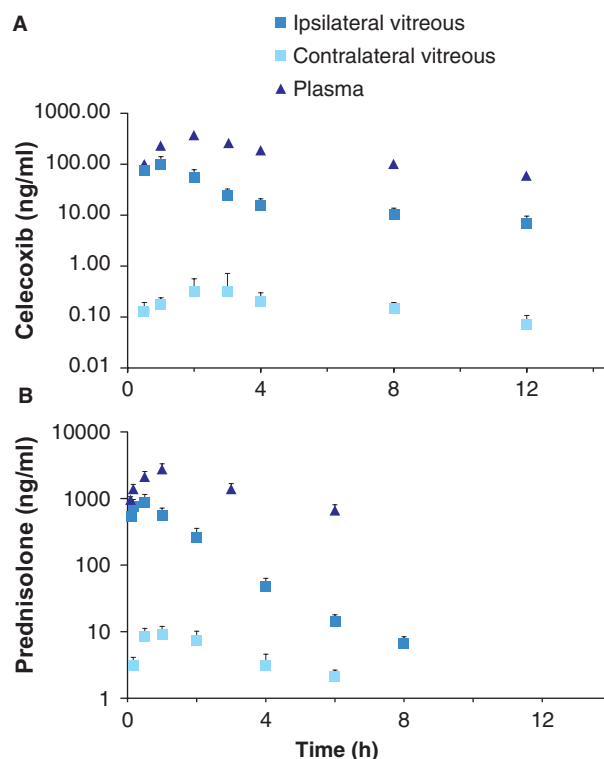
AUC: Area under the curve; SC: Subconjunctivally.

detachment revealed that subconjunctival injection is more effective in delivering dexamethasone disodium phosphate into the subretinal fluid (Table 3) compared with peribulbar injection or oral administration [43]. Corrected for dose, the maximum dexamethasone concentration after subconjunctival injection and peribulbar injection were, respectively, 120 and 13 times greater than oral administration.

Thus, periocular administration delivers more dexamethasone phosphate to the posterior segment compared with systemic or topical administration in humans.

### 3.5 Local retinal delivery is predominant following periocular administration

Substantially higher drug levels in the retina can be attained following subconjunctival administration as compared with the systemic route. A study towards this end in the authors' laboratory quantified the relative retinal bioavailability of celecoxib from the subconjunctival route compared with the intraperitoneal route in rats (Figure 2) [44]. For the subconjunctivally dosed (ipsilateral) eye, the area under the curve ( $AUC_{0-\infty}$ ) ratios between subconjunctival and intraperitoneal groups were  $0.8 \pm 0.1$ ,  $53.1 \pm 3.5$ ,  $54.3 \pm 8.4$ ,  $144.5 \pm 21$ ,  $60.7 \pm 15.6$  and  $51.6 \pm 5.7$ , for plasma, sclera, retina, vitreous, lens and cornea, respectively. For the contralateral ocular tissues, the  $AUC_{0-\infty}$  ratios were  $1.2 \pm 0.2$ ,  $1.1 \pm 0.3$ ,  $1.1 \pm 0.4$ ,  $1 \pm 0.3$  and  $1.2 \pm 0.3$ , in the sclera, retina, vitreous, lens and cornea, respectively, between the subconjunctival and the intraperitoneal groups. Thus, the drug delivery to the retina and other ocular tissues is superior to systemic mode of administration



**Figure 3. Subconjunctival route for retinal delivery of drugs in rats and rabbits. (A)** Celecoxib levels in the vitreous and plasma of Sprague–Dawley rats following subconjunctival injection of a 50  $\mu$ l suspension containing 3 mg drug. The data are expressed as mean  $\pm$  s.d. for  $n = 4$  [44]. **(B)** Prednisolone levels in various tissues after subconjunctival injection of a 50  $\mu$ l solution containing prednisolone at 1 mg/kg dose in New Zealand white rabbits. The data are expressed as mean  $\pm$  s.e.m. for  $n = 3$  [45].

by  $> 50$ -fold for celecoxib. Assuming that the drug AUCs in contralateral eye were equal to the systemic pathway contribution to AUCs in the ipsilateral eye, the percentage contribution of local pathways as opposed to systemic circulation for celecoxib delivery to the ipsilateral eye tissues was estimated to be  $\geq 98\%$ . Thus, the contribution of systemic recirculation pathway to the drug levels in the intraocular tissues following subconjunctival injection is negligible for celecoxib in rats. Figure 3A shows drug levels in the rat vitreous following subconjunctival administration of 3 mg of celecoxib as a suspension in 0.5% carboxymethylcellulose [44]. The injection volume was 50  $\mu$ l. For comparative purposes, drug levels in the vitreous and serum for prednisolone administered subconjunctivally in a rabbit model are shown in Figure 3B [45]. It can be seen that the two models have provided similar information about the two drugs – that is, vitreal drug levels following the subconjunctival route of administration are contributed primarily by local delivery or diffusion across local barriers as opposed to delivery via the systemic recirculation pathway. In both animal models, significant vitreous:plasma/serum AUC ratios were observed for the drugs in the ipsilateral eyes.

Table 4. Properties of human sclera.

Property	Value	Reference
<b>Surface area</b>		
Computerised tracings	16.3 ± 1.8 cm <sup>2</sup>	[51]
Volume displacement	17.0 ± 0.5 cm <sup>2</sup>	
<b>Thickness</b>		
At limbus	0.53 ± 0.14 mm	[52]
Near the equator	0.39 ± 0.17 mm	
Near the optic nerve	0.9 – 1.0 mm	
Structural composition	Collagen fibres (up to 75% dry weight), water (68%), mucopolysaccharides (0.7 – 0.9% dry weight), proteoglycans, elastic fibres and fibroblasts	
Highest molecular weight known to permeate sclera	70,000	

Thus, in the rat and rabbit models, periocularly administered drug reaches the tissues of the posterior segment primarily via local delivery as opposed to systemic pathway.

### 3.6 Periocular routes for macromolecule delivery

Macromolecule delivery to the intraocular tissues can be achieved following periocular administration [46]. The serum concentration from a retrobulbar injection of IFN- $\alpha_{2a}$  were reported to be < 1% of the choroidal concentration, and it was suggested that the retrobulbar route can be used to deliver IFN- $\alpha_{2a}$  for the treatment of choroidal neovascularisation. Ambati *et al.* demonstrated that the retinal delivery of a macromolecule (fluorescein isothiocyanate [FITC]-labelled IgG) can be sustained from the subconjunctival space in a rabbit model [47]. An osmotic pump was used to deliver IgG across the sclera of pigmented rabbits, and IgG levels were measured in various tissues over 28 days. They observed that the drug was localised more to the choroid proximal to the injection site compared with the distal choroid. Interestingly, the macromolecule persisted in the choroid and retina for a long period, as indicated by the elimination half-life of the macromolecule, which was of the order of days from choroid and the retina following the cessation of drug delivery. Maurice [48] demonstrated that the removal of macromolecules from the subretinal space is slow, with 80% of FITC-dextran 150S being detectable at the end of 3 days following subretinal injection in rabbits with experimental non-rhegmatogenous retinal detachments. Carboxyfluorescein, on the other hand, was not detectable in the subretinal space after 8 h. Although trace quantities of FITC-dextran 150S were detected in the vitreous of this model, significant quantities of FITC-dextran 70S and carboxyfluorescein were detectable in the vitreous.

Using the then available limited means, as early as 1978, Maurice has obtained evidence that whereas small ions can disappear from the subconjunctival space within a few minutes, macromolecules are retained for prolonged periods [37]. Following subconjunctival administration of immunoglobulin, another group observed peak levels of the protein in the cornea on day 6, suggesting prolonged retention of the

molecule in the subconjunctival space [49]. If the conjunctiva is less permeable to macromolecules compared with sclera, it may benefit trans-scleral macromolecule delivery following periocular administration.

Some macromolecules administered by the periocular route may not reach the neural retina due to the presence of the retinal pigment epithelium. Gelbach *et al.* [50] observed that periocular administration of an adenoviral vector encoding pigment epithelium-derived factor (PEDF) resulted in high levels of PEDF in the retinal pigment epithelium (RPE) and choroid, but not in the retina. Periocular gene delivery systems express protein in the periocular region, leading to protein secretion followed by diffusion across sclera into the tissues of the posterior segment.

Thus, macromolecules permeate the sclera and they exhibit prolonged residence in the subconjunctival and subretinal spaces. In addition, they are known to be cleared slowly from the vitreous [32]. The RPE layer is rate-limiting in the delivery of macromolecules to the neural retina. Thus, retinal delivery of macromolecules poses unique challenges and opportunities.

## 4. Mechanisms of trans-scleral drug delivery

Trans-scleral delivery is less invasive to the eye compared with intravitreal injection, and it provides local delivery of high-molecular-weight compounds to the posterior segment. Human sclera is hypocellular and has a large surface area, both of which facilitate diffusion (Table 4) [51,52]. The primary route for solute transport through the sclera is by passive diffusion through an aqueous pathway. Figure 4 [53-57] summarises the permeability coefficients for several solutes across human sclera. Henry Edelhauser contributed substantially in understanding various aspects of trans-scleral drug delivery, including scleral permeability, scleral surface area, scleral thickness and the usefulness of depot systems in trans-scleral drug delivery [52].

Intraocular distribution of a 70 kDa tetramethylrhodamine-dextran (TMR-D) after subconjunctival injection was studied in mice [58] to determine the mechanisms of drug delivery.

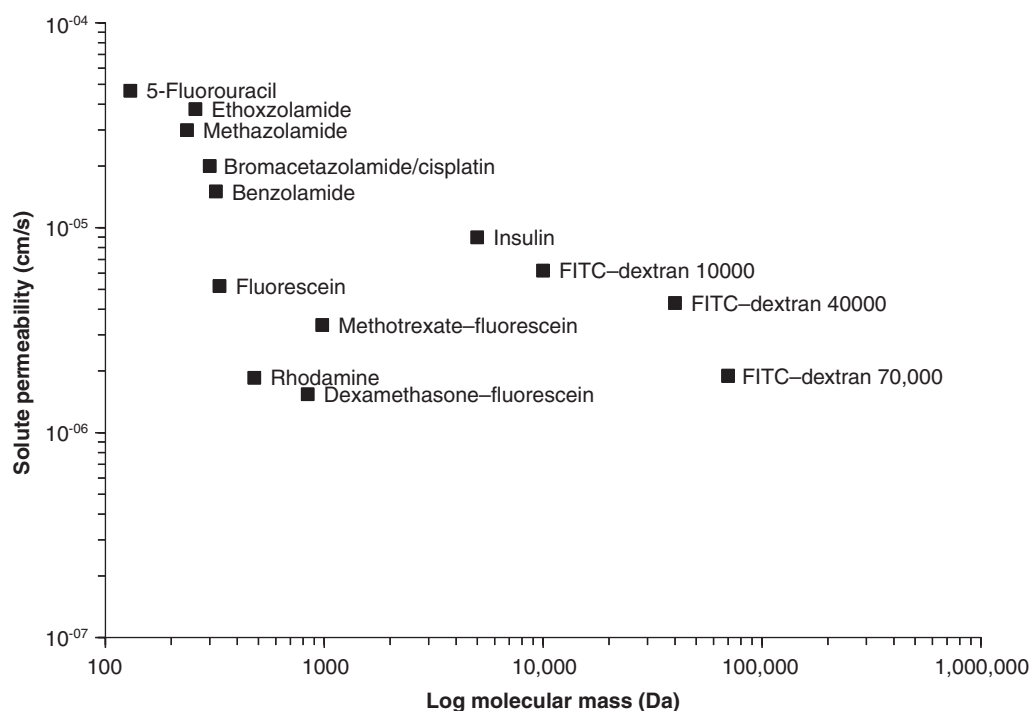


Figure 4. Permeabilities of various solutes across human sclera [53-57].

TMR-D readily diffused trans-sclerally and dispersed throughout a large portion of the sclera, uvea and cornea. Shortly after the injection, homogenous fluorescence was observed in the sclera and choroid on the same meridian as that of the injection site. This fluorescence gradually decreased in intensity with distance from the injection site. The intensity of scleral and choroidal fluorescence adjacent to the optic nerve reached a maximum at 1 h and then decreased slowly, with half-lives of ~ 16 and 100 h, respectively. Visible fluorescence was maintained for at least 72 h in the sclera, choroid, iris and cornea. Based on this, it was concluded that macromolecular 70 kDa dextran can be delivered to the mouse retina and uveal tissues following subconjunctival injection through trans-scleral diffusion, local hematogenous spread, and possibly movement through the uveo-scleral outflow pathway.

The various major pathways that a drug can traverse following periocular administrations are summarised in Figure 5. There are several barriers that the drug can encounter after diffusing across the sclera. After crossing the sclera, the tissues encountered by the drug include choroid, retinal pigment epithelium, outer limiting membrane, neural retina, inner limiting membrane, and the vitreous in that order. Depending on the target site, the drug has to cross one or more of the intermittent layers. Several of these can pose significant barriers for retinal drug delivery, with choroidal blood flow and retinal pigment epithelial barriers being the most significant. The vascular supply in the choroid is likely to clear

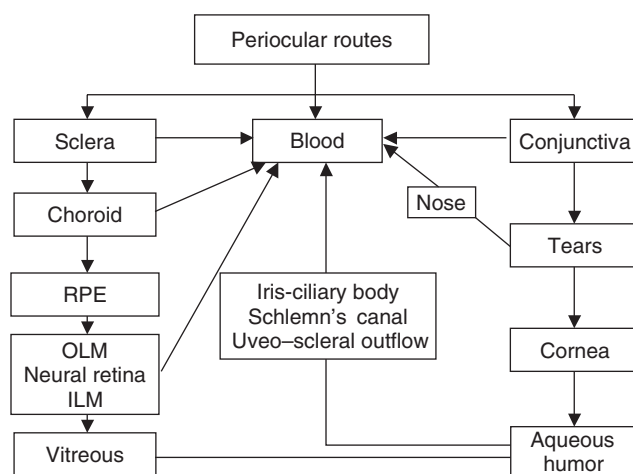
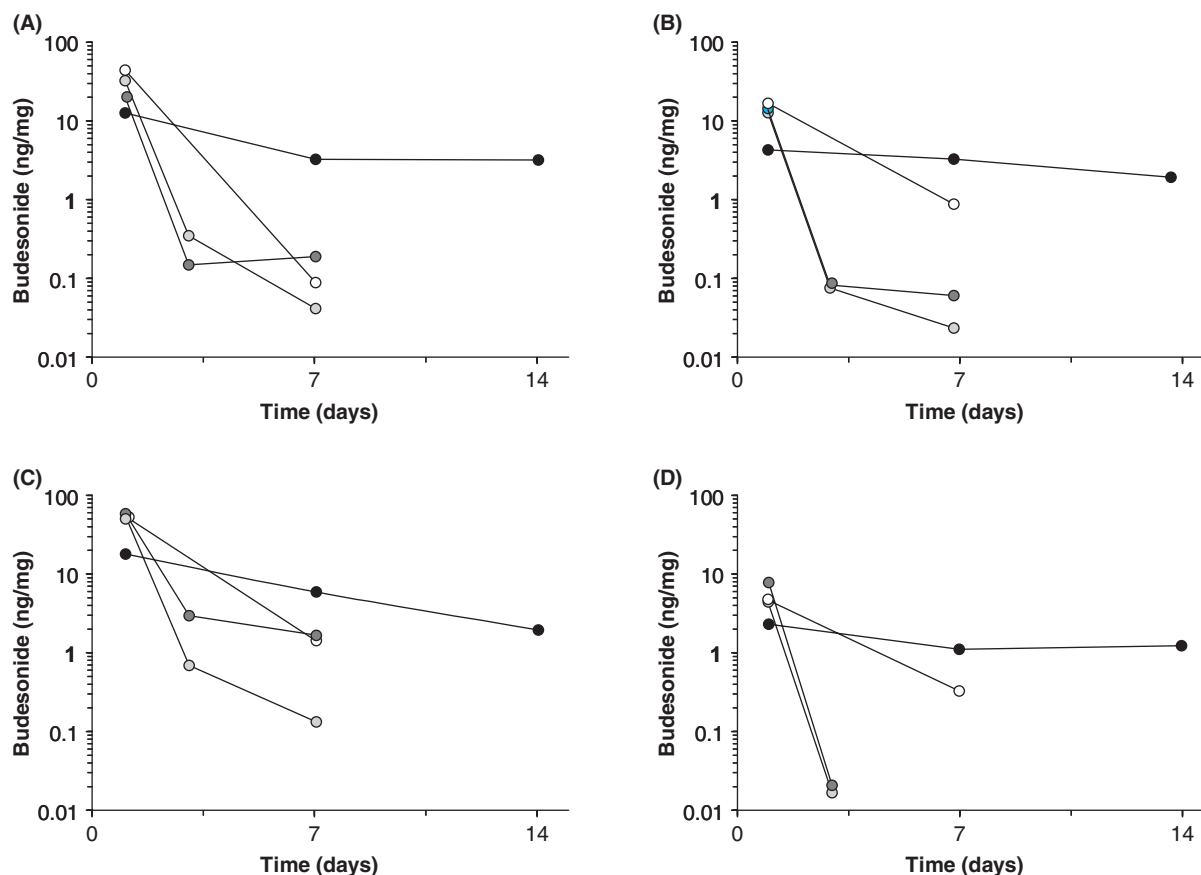


Figure 5. Pathways for intraocular and systemic delivery of drugs following periocular administration.

ILM: Inner limiting membrane; OLM: Outer limiting membrane; RPE: Retinal pigment epithelium.

the drug rapidly. Early on, the investigations of Maurice indicated that application of local pressure to the subconjunctival site of drug administration can elevate the drug delivery to the posterior segment, by reducing local choroidal blood flow [59]. With the application of pressure at the site of subconjunctival administration in rabbits at 10 min post-injection for 25 min,



**Figure 6. Budesonide nano- and microparticles sustained ocular tissue levels of budesonide after subconjunctival administration in rats.** Budesonide was administered in the eyes of rats, either in the form of a solution (50 or 75 µg to one eye; white and light grey circles, respectively), nanoparticles (50 µg to one eye; dark grey circles), or microparticles (75 µg to one eye; black circles), and drug levels were estimated in (A) retina, (B) vitreous, (C) cornea and (D) lens. Data are expressed as the mean ± s.d. of results in four experiments. Data are shown for the ipsilateral eye. Drug levels were below detection limits in the contralateral eye. Budesonide levels were below detection limits on day 14 in the solution and nanoparticle groups. Reproduced with permission from KOMPELLA UB, BANDI N, AYALASOMAYAJULA SP: Subconjunctival nano- and microparticles sustain retinal delivery of budesonide, a corticosteroid capable of inhibiting VEGF expression. *Invest. Ophthalmol. Vis. Sci.* (2003) **44**(3):1192-1201, Copyright © Association for Research in Vision and Ophthalmology [62].

the peak vitreal concentrations of fluorescein and carboxyfluorescein were elevated by 19- and 4-fold, respectively. Thus, a reduction in choroidal blood flow can substantially enhance the drug delivery to the posterior segment. In addition, the clearance of fluorescein, but not carboxyfluorescein, was reduced by threefold following application of pressure at the subconjunctival site. The retinal pigment epithelium, the outer blood-retinal barrier, is another significant barrier that a drug has to surpass following periocular administration prior to entering the neural retina. The RPE layer has tight intercellular junctions that restrict the movement of solutes, especially macromolecules. The entry of FITC-dextran 70 and 150S from the subretinal space into the vitreous was significantly elevated following disruption of the RPE layer with intravenous sodium iodate in an experimental rhegmatogenous retinal detachment rabbit model [48], consistent with the

rate-limiting nature of RPE for solute permeability. If macromolecules cross the RPE layer due to special transport mechanisms and/or high concentration gradients, their movement into the neural retina may be hindered by the inner limiting membrane [50]. If the drug target is in the choroid or the retinal pigment epithelium, those sites would be more readily accessible compared with the neural retina or the vitreous humor following periocular injections. If a drug is lipophilic, or if it binds to the pigment in the choroid or retinal pigment epithelium, only a fraction of the drug present in the tissue will be entering the vitreous humor. Entry of macromolecules into the vitreous from the neural retina is also restricted by the outer limiting membrane. Due to the presence of these multiple tissue layers, it is not surprising that drugs were detected in low concentrations in the vitreous following periocular administrations.

In addition to the aforementioned delivery of the drug to the tissues of the posterior segment, drug could permeate the conjunctiva, especially following subconjunctival administration, and enter the tear film and tissues of the anterior segment (Figure 5). At various locations, including the site of administration, episclera, conjunctiva, choroid and retina, drug could be lost to the blood circulation. Minimisation of these losses would better retain the drug in the tissues of the posterior segment.

Thus, human sclera is highly permeable, which allows the delivery of even macromolecules to the intraocular tissues. The underlying choroid circulation and retinal pigment epithelium, which are likely to be the major rate-limiting steps in the drug delivery to the neural retina and vitreous, deserve further investigations with respect to their role in trans-scleral drug delivery. In addition, as drug loss to the circulation at the site of administration limits the drug absorption into the intraocular tissues, the mechanisms of drug loss at each periocular site and approaches to overcome these need to be investigated.

## 5. Sustained release systems for periocular delivery

Prolonging the retention of the drug in the periocular regions can provide sustained drug levels and enhanced drug absorption into the intraocular tissues. Sasaki *et al.* [60] demonstrated that periocular injections containing 3% carboxymethylcellulose (CMC) as a viscous vehicle decreased the absorption rate constant of tilisolol, a model  $\beta$ -blocker, from the injection site to the systemic circulation compared with the buffer solution [61]. Compared with the results after periocular injections with buffer solution, CMC increased the AUCs in the vitreous body 3.1-fold with retrobulbar injection and 1.4-fold with palpebral conjunctival injection, respectively. Thus, it is likely that various adjuvants in the formulations administered periocularly can influence drug delivery.

Chronic ocular disorders can most efficiently be managed by maintaining the drug concentrations within the therapeutic window at the target site in the eye and reducing the frequency of administrations. To address this aspect of ocular drug delivery, a large number of sustained and controlled release drug delivery systems, namely implants, gels, microparticles and nanoparticles, are being investigated. Implants can release drug either in one direction (towards sclera) or from all sides. Implants can be placed either episclerally or intrasclerally after thinning the sclera. Gels can be based on several polymeric materials including biopolymers such as fibrin. Similar to the intravitreal route, a long-term trans-scleral delivery device may be clinically feasible because the human eye is tolerant of some materials overlying the sclera, such as scleral buckles used in treating retinal detachment, even for years.

Subconjunctival injection of drug-loaded microparticles and nanoparticles can also be employed for sustained retinal drug delivery [62]. The authors have previously shown that

subconjunctivally administered budesonide-poly(lactide) (budesonide-PLA) nano- and microparticles sustain retinal drug delivery. Ocular tissue levels of budesonide were compared after a single subconjunctival injection of either budesonide solution (containing 50 or 75  $\mu\text{g}$  of budesonide), budesonide-PLA nanoparticles (containing 50  $\mu\text{g}$  of budesonide) or budesonide-PLA microparticles (containing 75  $\mu\text{g}$  of budesonide), and drug levels were estimated up to 14 days (Figure 6) [62]. With budesonide-PLA nanoparticles, the retinal levels of budesonide were 2- and 9-times higher than the budesonide solution-treated groups at the end of 3 and 7 days, respectively. The nanoparticles group had a 5.5-times higher vitreous budesonide concentration compared with the budesonide solution-treated group at the end of day 7. At the end of days 3 and 7, the corneal levels of budesonide with the nanoparticle formulation were 4- and 27-times higher than that of the budesonide solution-treated group. On comparison of subconjunctival injection of budesonide-PLA microparticles (75  $\mu\text{g}$  budesonide dose) to subconjunctival injection of budesonide solution (75  $\mu\text{g}$  budesonide dose), it was found that on day 1, drug levels in the solution group were 3.5-, 5.5-, 3- and 2-times higher in the retina, vitreous, cornea and lens, respectively, when compared with microparticle group ( $p < 0.05$  for all tissues). On day 7, drug levels in the microparticle group were 37-, 5-, 4.2- and 3.4-times higher in the retina, vitreous, cornea and lens, respectively, compared with the solution group. Similarly on day 14, drug levels in the microparticle group were higher compared with the solution group, wherein the drug levels were  $3.5 \pm 1.14$ ,  $0.8 \pm 0.21$ ,  $1.9 \pm 0.3$  and  $1.2 \pm 0.25$  ng/mg tissue weight in retina, vitreous, cornea and lens, respectively [62]. Microparticles better sustained drug delivery compared with the nanoparticles.

For sustained retinal drug delivery, it is hypothesised that those particles that are retained in the periocular space would be more appropriate. This is because if the particles are not cleared, they can release the drug over a prolonged period for subsequent delivery to the tissues of the posterior segment. The periocular retention of particles depends on their size. Microparticles (2  $\mu\text{m}$ ) are almost completely retained in the periocular space even at 2 months post-administration, whereas nanoparticles (20 nm) completely disappear from the periocular space [63]. Neither microparticles nor nanoparticles of the above dimensions enter the intraocular tissues to a significant extent from the periocular space. Future studies should elucidate the mechanisms of clearance of particulate systems from the periocular space.

Saishin *et al.* [64] investigated the sustained local delivery of PKC412, a kinase inhibitor, following periocular injection of poly(lactide-co-glycolide) microspheres containing 25 or 50% PKC412 in a porcine model. The levels of PKC412 attained after 20 days following periocular injection of 25% microspheres were 1.2 ng/ml vitreous, 0.5 ng/retina, and 2 ng/choroid, respectively, whereas those with 50% microspheres were 35 ng/ml vitreous, 19 ng/retina and

155 ng/choroid, respectively. In plasma, the levels of PKC412 20 days post-injection were undetectable.

Feasibility of drug delivery to the posterior segment of the rabbit eye with an episcleral implant capable of delivering the drug in one direction towards the sclera was evaluated for betamethasone [65]. Such a system minimises the drug loss to the conjunctival circulation. The implant showed a zero-order release profile both *in vitro* and *in vivo* for 4 weeks. Betamethasone concentrations in the retina choroid after implantation were maintained above concentrations effective for suppressing inflammatory reactions for at least 4 weeks. The drug concentration was greater in the posterior half of retina-choroid than in the vitreous. In the vitreous, the maximum concentration was 13 ng/g at 2 weeks after implantation.

In brief, several sustained-release drug delivery systems including gels, particulate systems and implants have been shown to sustain the drug delivery to the retina following periocular administration. As repeated periocular administrations would be inconvenient, drug delivery systems capable of sustaining drug delivery for a few months to years are desirable.

## 6. Pharmacodynamics

Posterior sub-tenon's steroid injections (PSTSI) are a standard drug delivery method used for the treatment of chronic uveitis of the posterior segment [66]. A retrospective study done in a uveitis clinic to analyse the indications, efficacy and complications of PSTSI in the treatment of chronic uveitis concluded that PSTSI are very effective in restoring visual acuity in chronic uveitis of the posterior segment, without systemic complications, but at the expense of intraocular hypertension. An intravenous cannula made of polytetrafluoroethylene has been used to inject corticosteroids safely into the posterior sub-tenon space [67].

Studies have shown that posterior sub-tenon's injection of corticosteroids significantly decreases cystoid macular oedema [68]. The first study reported in the UK to investigate the efficacy and safety of posterior sub-tenon triamcinolone acetate injection demonstrated that these injections significantly decrease cystoid macular oedema with a corresponding increase in visual acuity in patients with uveitis. Systemic immunosuppression may be reduced or discontinued with the avoidance of associated systemic side effects, and the technique has a high level of patient acceptability. A retrospective study performed to compare the effectiveness of retrobulbar and posterior sub-tenon's injection of corticosteroids for the treatment of post-cataract cystoid macular oedema that was refractory to topical medications found that both treatment methods resulted in significant improvement in visual acuity. There was no significant difference between the improvement in cystoid macular oedema achieved after retrobulbar or posterior sub-tenon's corticosteroid injections [69].

In a masked, randomised, placebo-controlled study, anecortave acetate depot suspension administered posteriorly juxtasclerally was assessed for its benefits in patients with subfoveal choroid neovascularisation (CNV) [23]. It was observed that at month 12, a 15 mg dose of the drug administered at 6-month intervals was superior to the placebo in maintaining vision, preventing severe vision loss and inhibiting subfoveal CNV lesion growth.

Ambati *et al.* demonstrated that an osmotic pump containing mouse antihuman intercellular adhesion molecule (ICAM)-1 mAb exerts pharmacological effects in the retina and choroid following subconjunctival administration [47]. VEGF-induced leucostasis in the retina and choroid, as measured by myeloperoxidase activity, was inhibited by the delivery of anti-ICAM-1 mAb. Myeloperoxidase activity in the choroid of the eye treated with anti-ICAM-1 mAb (2 mg/ml delivered at 8 µl/h) was 80% less than in the eye receiving an equal rate of delivery of an isotype control antibody (n = 5). Inhibition of myeloperoxidase activity in the retina was 70% (n = 5).

Ayalasomayajula and Kompella demonstrated that celecoxib-containing poly(lactide-co-glycolide) microparticles sustain the retinal delivery of celecoxib and inhibit oxidative stress in a diabetic rat model [70]. Saishin *et al.* [64] demonstrated the effectiveness of periocularly injected poly(lactide-co-glycolide) microspheres containing 25 or 50% PKC412 in a porcine model. The areas of choroid neovascularisation at Bruch's membrane rupture sites were significantly smaller in eyes that received a periocular injection of microspheres containing 25 or 50% PKC412 than those in eyes injected with control microspheres. These data suggested that trans-scleral sustained delivery of agents is a viable approach for treatment of choroidal diseases.

Periocularly-injected adenoviral vector encoding VEGF receptor-1, sFlt-1 (ADsFlt-1.10), has been shown to be effective in a mouse model for choroid neovascularisation [50]. Periocular injection of ADsFlt-1.10 markedly suppressed choroidal neovascularisation at rupture sites in Bruch's membrane and also caused significant reduction in VEGF-induced breakdown of the blood-retinal barrier, but failed to significantly inhibit ischaemia-induced retinal neovascularisation. The lack of effect on retinal neovascularisation is possibly because the secreted protein did not cross the retinal pigment epithelium to reach the neural retina.

Thus, there is growing evidence indicating the effectiveness of periocularly-administered drugs in alleviating uveitis, cystoid macular oedema, choroid neovascularisation and diabetic retinal changes.

## 7. Future challenges

As the work of Lee and Robinson [6,33,34] has indicated, the fraction of drug absorbed can be reduced by the rapid loss of the drug from the periocular sites into the systemic circulation, prior to drug entry into the intraocular tissues via the sclera. To overcome this, systems that deliver the drug unidirectionally

towards the sclera while eliminating the drug entry into the systemic circulation would be beneficial. Kim *et al.* [71], using a non-invasive magnetic resonance imaging study, reported that from an episcleral implant, 30-fold greater vitreous solute levels can be achieved at the end of 4 h in a rabbit used post-mortem compared with a live rabbit. This finding suggests that the blood circulation in various layers of the eye limits trans-scleral drug delivery *in vivo*. In future, approaches need to be developed to overcome this limitation. Alternatively, a breach in the retinal pigment epithelial barrier during the course of the study following euthanasia can explain these results. The retinal pigment epithelial barrier is likely to be more formidable *in vivo* than any currently available cell culture models indicate. To further improve the penetration of the drug into intraocular tissues, various absorption enhancement approaches can be assessed for their safety and efficacy [72]. Because the periocular injections should be made in a way that does not perforate the globe, development of better administration devices would be helpful. As several ophthalmic industries have expertise in drug and device development, this may come naturally to these organisations. Traditionally, periocularly-administered drugs are mainly off-label uses of drug products developed for other routes of administration. As there are several chronic disorders that afflict the posterior segment of the eye, pharmaceutical industries should devote more resources to developing products primarily intended for administration by these routes.

## 8. Conclusions

Periocular routes of administration include subconjunctival, sub-tenon, peribulbar, retrobulbar and posterior juxtasceral modes. Drugs administered by these routes can be transported across sclera to the tissues of the posterior segment. The choice of these routes depends on the intended purpose and target tissues. There is limited pharmacokinetic and pharmacodynamic data with these routes. Current literature indicates that the drug delivery to the posterior segment is generally superior by this route compared with topical and systemic routes. Potent drug molecules can potentially be delivered by this approach for their effects in various tissues of the posterior segment. As repeated injections by these routes

would be inconvenient and increase the risk potential, sustained release systems are being developed for treating various chronic disorders of the posterior segment.

## 9. Expert opinion

The retina is a relatively inaccessible tissue to the blood circulation, not unlike the brain tissue. Drugs intended for effects in the brain are routinely administered orally. Such is not the case for the retina, as drug discovery and development efforts typically do not focus on the design of orally administered drugs that are safe and effective in the retina. Instead, drugs developed for other systemic diseases are usually assessed for their retinal effectiveness. In the absence of eye-specific drug design, retinal delivery can be enhanced using multiple approaches including the periocular routes of administration. In general, periocular routes can deliver the drug better to the retina compared with the systemic or topical modes of administration. The concerns associated with periocular routes include the fraction of drug absorbed and safety. Administration by skilled operator along with the use of technologies such as sonography can reduce the risks associated with the periocular modes of administration. Even with existing safety issues for periocular routes, these routes are potentially much safer than the intravitreal mode of administration, which is the current route of choice for providing high drug levels to the retina. Each route has its place in drug delivery and the choice of route should be based on the disease target (e.g., vitreous versus choroid) and the nature of the disease (e.g., acute versus chronic). If acute therapy is desired, intravitreal injections are viable. For chronic therapy, intravitreal implants or periocular sustained release systems that maintain drug levels for months to several years would be suitable. Repeated administrations are likely to be more amenable and safe with periocular routes.

## Acknowledgements

This work was supported by NIH grants DK064172, DK064172-02S1 and EY013842. The authors wish to thank UNMC for awarding graduate fellowship to S Raghava, and Drs C Camras and E Margalit of UNMC for a critical review of this manuscript.

## Bibliography

Papers of special note have been highlighted as of interest (•) to readers.

1. KOMPPELLA UB, LEE VHL: Barriers to drug transport in ocular epithelia: In: *Transport processes in pharmaceutical systems*. Amidon GL, Lee PI, Topp EM (Eds), Marcel Dekker, Inc., New York, USA (1999):317-376.
2. SUNKARA G, KOMPPELLA UB: Membrane transport processes in the eye. (Second) *Ocular Drug Delivery Systems*. Mitra AK (Ed.), Marcel Dekker, Inc., New York, USA (2003):13-58.
3. DENNINGHOFF KR, SMITH MH, LOMPADO A, HILLMAN LW: Retinal venous oxygen saturation and cardiac output during controlled hemorrhage and resuscitation. *J. Appl. Physiol.* (2003) **94**(3):891-896.
4. RENNIE IG: Clinically important reactions to systemic drug therapy. *Drug Saf.* (1993) **9**(3):196-211.
5. DAVIDSON SI, RENNIE IG: Ocular toxicity from systemic drug therapy. An overview of clinically important adverse

- reactions. *Med. Toxicol.* (1986) 1(3):217-224.
6. LEE TW, ROBINSON JR: Drug delivery to the posterior segment of the eye: some insights on the penetration pathways after subconjunctival injection. *J. Ocul. Pharmacol. Ther.* (2001) 17(6):565-572.
- **Elucidated the mechanisms of trans-scleral delivery.**
7. PEYMAN GA, VASTINE DW, MEISELS HI: The experimental and clinical use of intravitreal antibiotics to treat bacterial and fungal endophthalmitis. *Doc. Ophthalmol.* (1975) 39(1):183-201.
8. CAMPOCHIARO PA, CONWAY BP: Aminoglycoside toxicity – a survey of retinal specialists. Implications for ocular use. *Arch. Ophthalmol.* (1991) 109(7):946-950.
9. VELEZ G, WHITCUP SM: New developments in sustained release drug delivery for the treatment of intraocular disease. *Br. J. Ophthalmol.* (1999) 83(11):1225-1229.
10. LEEDS JM, HENRY SP, TRUONG L *et al.*: Pharmacokinetics of a potential human cytomegalovirus therapeutic, a phosphorothioate oligonucleotide, after intravitreal injection in the rabbit. *Drug Metab. Dispos.* (1997) 25(8):921-926.
11. ROBERTSON JE, WESTRA I, WOLTERING EA *et al.*: Intravitreal injection of octreotide acetate. *J. Ocul. Pharmacol. Ther.* (1997) 13(2):171-177.
12. KWAK HW, D'AMICO DJ: Evaluation of the retinal toxicity and pharmacokinetics of dexamethasone after intravitreal injection. *Arch. Ophthalmol.* (1992) 110(2):259-266.
13. BARZA M, LYNCH E, BAUM JL: Pharmacokinetics of newer cephalosporins after subconjunctival and intravitreal injection in rabbits. *Arch. Ophthalmol.* (1993) 111(1):121-125.
14. KOMPELLA UB, LEE VHL: Pharmacokinetics of peptide and protein drugs. In: *Peptide and protein drug delivery (1<sup>st</sup> edn)*. Lee VHL (Ed.), Marcel Dekker Inc., New York, USA (1991):391-484.
15. Anesthesia and akinesia for eye operations. In: *Stallard's Eye Surgery (7<sup>th</sup> edn)*. Roper-Hall MJ (Ed.), Wright & Sons Ltd, Bristol, UK (1989):44-63.
- **Explains anatomical locations of various periocular injection sites in an easily understandable and comprehensive manner.**
16. HAMILTON R: Retrobulbar and periocular anesthesia for cataract surgery. In: *Cataract surgery: technique, complications, management (2<sup>nd</sup> edn)*, RF S Elsevier Science, Philadelphia, USA (2004):79-95.
17. *Physiology of the eye: an introduction to the vegetative functions (2<sup>nd</sup> edn)*. Fatt I, Weissman BA, Butterworth-Heinemann, Inc., Stoneham, USA (1992):2-3.
18. CANAVAN KS, DARK A, GARRIOCH MA: Sub-Tenon's administration of local anaesthetic: a review of the technique. *Br. J. Anaesth.* (2003) 90(6):787-793.
19. *Cataract surgery and its complications (6<sup>th</sup> edn)*. Jaffe NS, Jaffe MS, Jaffe GF, Craven L Mosby-Year Book, Inc, St. Louis, USA (1997):20-25.
20. ZAHL K: Selection of techniques for regional blockade of the eye and adnexa. In: *Anesthesia for ophthalmic and otolaryngologic surgery*, McGoldrick KE (Ed.), WB Saunders Co., Philadelphia, USA (1992):235-247.
21. *Eye surgery: an introduction to operative technique (2<sup>nd</sup> edn)*. Eisner G, Springer-Verlag, Berlin, Germany (1990):119-123.
22. STEAD S, MILLER KM: Anesthesia for ophthalmic surgery. *Ophthalmic Surgery: Principles and Practice (3<sup>rd</sup> edn)*. Spaeth G (Ed.), WB Saunders, Philadelphia, USA (2003):15-25.
23. GROUP TAACS: Anecortave acetate as monotherapy for treatment of subfoveal neovascularization in age-related macular degeneration. *Ophthalmology* (2003) 110:2372-2385.
- **A clinical report on juxtascally administered anecortave acetate. A trend-setting study.**
24. CHANG WM, STETTEN GD, LOBES LA Jr, SHELTON DM, TAMBURO RJ: Guidance of retrobulbar injection with real-time tomographic reflection. *J. Ultrasound Med.* (2002) 21(10):1131-1135.
25. SCHOENWALD RD: Ocular pharmacokinetics and pharmacodynamics. *Ophthalmic Drug Delivery Systems (2<sup>nd</sup> edn)*. Mitra AK (Ed.), Marcel Dekker, New York, USA (2003):135-179.
- **Explains the challenges and fundamentals of ocular pharmacokinetics.**
26. MAURICE DM: Drug delivery to the posterior segment from drops. *Surv. Ophthalmol.* (2002) 47:S41-S52.
- **A critical review of literature reports claiming drug delivery to the back of the eye from topical drops.**
27. ISHII K, MATSUO H, FUKAYA Y *et al.*: Iganidipine, a new water-soluble Ca<sup>2+</sup> antagonist: ocular and periocular penetration after instillation. *Invest. Ophthalmol. Vis. Sci.* (2003) 44(3):1169-1177.
28. KAPIN MA, YANNI JM, BRADY MT *et al.*: Inflammation-mediated retinal edema in the rabbit is inhibited by topical nepafenac. *Inflammation* (2003) 27(5):281-291.
29. TAKAHASHI K, SAISHIN Y, MORI K *et al.*: Topical nepafenac inhibits ocular neovascularization. *Invest. Ophthalmol. Vis. Sci.* (2003) 44(1):409-415.
30. KOEVARY SB, LAM V, PATSIPOULOS G: Pharmacokinetics of insulin uptake by ocular tissues and the role of cerebrospinal fluid in optic nerve insulin accumulation following topical insulin application. *Optometry* (2004) 75(3):183-188.
31. AHMED I, PATTON TF: Importance of the noncorneal absorption route in topical ophthalmic drug delivery. *Invest. Ophthalmol. Vis. Sci.* (1985) 26(4):584-587.
32. MAURICE D: Review: practical issues in intravitreal drug delivery. *J. Ocul. Pharmacol. Ther.* (2001) 17(4):393-401.
- **An analytical paper discussing the limitations of intravitreal depot systems.**
33. LEE TW, ROBINSON JR: Drug delivery to the posterior segment of the eye III: the effect of parallel elimination pathway on the vitreous drug level after subconjunctival injection. *J. Ocul. Pharmacol. Ther.* (2004) 20(1):55-64.
34. LEE TW, ROBINSON JR: Drug delivery to the posterior segment of the eye II: development and validation of a simple pharmacokinetic model for subconjunctival injection. *J. Ocul. Pharmacol. Ther.* (2004) 20(1):43-53.
35. Physician's Desk Reference (2003).
36. CHAPLIN MD: Bioavailability of nafarelin in healthy volunteers. *Am. J. Obstet. Gynecol.* (1992) 166(2):762-765.
37. MAURICE DM, OTA Y: The kinetics of subconjunctival injections. *Jpn. J. Ophthalmol.* (1978) 22:95-100.
38. BARZA M, KANE A, BAUM JL: Regional differences in ocular concentration of gentamicin after subconjunctival and retrobulbar injection in the rabbit. *Am. J. Ophthalmol.* (1977) 83(3):407-413.
- **An example of pioneering periocular pharmacokinetic studies.**

39. WINE NA, GORNALL AG, BASU PK: The ocular uptake of subconjunctivally injected C14 hydrocortisone. Pt. 1. Time and major route of penetration in a normal eye. *Am. J. Ophthalmol.* (1964) **58**:362-366.
40. BARZA M: Antibacterial agents in the treatment of ocular infections. *Infect. Dis Clin. North Am.* (1989) **3**(3):533-551.
  - **A comprehensive summary of Barza's work and periocular pharmacokinetics until 1989.**
41. WEIJTENS O, FERON EJ, SCHOEMAKER RC *et al.*: High concentration of dexamethasone in aqueous and vitreous after subconjunctival injection. *Am. J. Ophthalmol.* (1999) **128**(2):192-197.
  - **A key clinical pharmacokinetic study.**
42. WEIJTENS O, SCHOEMAKER RC, ROMIJN FP *et al.*: Intraocular penetration and systemic absorption after topical application of dexamethasone disodium phosphate. *Ophthalmology* (2002) **109**(10):1887-1891.
  - **A key clinical pharmacokinetic study.**
43. WEIJTENS O, SCHOEMAKER RC, LENTJES EG *et al.*: Dexamethasone concentration in the subretinal fluid after a subconjunctival injection, a peribulbar injection, or an oral dose. *Ophthalmology* (2000) **107**(10):1932-1938.
  - **A key clinical pharmacokinetic study.**
44. AYALASOMAYAJULA SP, KOMPELLA UB: Retinal delivery of celecoxib is several-fold higher following subconjunctival administration compared to systemic administration. *Pharm. Res.* (2004) **21**(10): 1790-1796.
45. TSUJI A, TAMAI I, SASAKI K: Intraocular penetration kinetics of prednisolone after subconjunctival injection in rabbits. *Ophthalmic Res.* (1988) **20**(1):31-43.
  - **A comprehensive subconjunctival pharmacokinetic study.**
46. LINCOFF H, STANGA P, MOVSHOVICH A *et al.*: Choroidal concentration of interferon after retrobulbar injection. *Invest. Ophthalmol. Vis. Sci.* (1996) **37**(13):2768-2771.
47. AMBATI J, GRAGLOUDAS ES, MILLER JW *et al.*: Transscleral delivery of bioactive protein to the choroid and retina. *Invest. Ophthalmol. Vis. Sci.* (2000) **41**(5):1186-1191.
48. MARMOR ME, NEGI A, MAURICE DM: Kinetics of macromolecules injected into the subretinal space. *Exp. Eye Res.* (1985) **40**(5):687-696.
49. OSUSKY R, MORELL A, IMBACH P, LERCH PG: Diffusion of immunoglobulins into rabbit cornea after subconjunctival injection: experimental demonstration and mathematical model. *Graefes Arch. Clin. Exp. Ophthalmol.* (1993) **231**(2):122-128.
50. GEHLBACH P, DEMETRIADES AM, YAMAMOTO S *et al.*: Periocular gene transfer of sFlt-1 suppresses ocular neovascularization and vascular endothelial growth factor-induced breakdown of the blood-retinal barrier. *Hum. Gene Ther.* (2003) **14**(2):129-141.
51. OLSEN TW, AABERG SY, GEROSKI DH, EDELHAUSER HF: Human sclera: thickness and surface area. *Am. J. Ophthalmol.* (1998) **125**(2):237-241.
52. GEROSKI DH, EDELHAUSER HF: Transscleral drug delivery for posterior segment disease. *Adv. Drug Deliv. Rev.* (2001) **52**(1):37-48.
  - **Provides a comprehensive review of transscleral drug delivery including the valuable contributions of Edelhauser.**
53. EDELHAUSER HF, MAREN TH: Permeability of human cornea and sclera to sulfonamide carbonic anhydrase inhibitors. *Arch. Ophthalmol.* (1988) **106**(8):1110-1115.
54. GILBERT JA, SIMPSON AE, RUDNICK DE *et al.*: Transscleral permeability and intraocular concentrations of cisplatin from a collagen matrix. *J. Control. Release* (2003) **89**(3):409-417.
55. CRUYSSBERG LP, NUIJTS RM, GEROSKI DH *et al.*: *In vitro* human scleral permeability of fluorescein, dexamethasone-fluorescein, methotrexate-fluorescein and rhodamine 6G and the use of a coated coil as a new drug delivery system. *J. Ocul. Pharmacol. Ther.* (2002) **18**(6):559-569.
56. OLSEN TW, EDELHAUSER HF, LIM JJ, GEROSKI DH: Human scleral permeability. Effects of age, cryotherapy, transscleral diode laser, and surgical thinning. *Invest. Ophthalmol. Vis. Sci.* (1995) **36**(9):1893-1903.
57. SHULER RK, JR, DIOGUARDI PK, HENJY C *et al.*: Scleral permeability of a small, single-stranded oligonucleotide. *J. Ocul. Pharmacol. Ther.* (2004) **20**(2):159-168.
58. KIM TW, LINDSEY JD, AIHARA M, ANTHONY TL, WEINREB RN: Intraocular distribution of 70-kDa dextran after subconjunctival injection in mice. *Invest. Ophthalmol. Vis. Sci.* (2002) **43**(6):1809-1816.
59. TSUKAHARA Y, MAURICE DM: Local pressure effects on vitreous kinetics. *Exp. Eye Res.* (1995) **60**(5):563-573.
60. SASAKI H, KASHIWAGI S, MUKAI T *et al.*: Drug absorption behavior after periocular injections. *Biol. Pharm. Bull.* (1999) **22**(9):956-960.
61. SASAKI H, KASHIWAGI S, MUKAI T *et al.*: Topical delivery system of ophthalmic drugs by periocular injection with viscous solution. *Biol. Pharm. Bull.* (1999) **22**(9):961-965.
62. KOMPELLA UB, BANDI N, AYALASOMAYAJULA SP: Subconjunctival nano- and microparticles sustain retinal delivery of budesonide, a corticosteroid capable of inhibiting VEGF expression. *Invest. Ophthalmol. Vis. Sci.* (2003) **44**(3):1192-1201.
63. AMRITE AC, AYALASOMAYAJULA SP, KOMPELLA UB: Microparticles but not nanoparticles are retained in the subconjunctival space at two months post administration. *Proceedings of the association for research in vision and ophthalmology annual meeting*. Ft. Lauderdale, Florida, USA (2004) Poster #5067/B391.
64. SAISHIN Y, SILVA RL, CALLAHAN K *et al.*: Periocular injection of microspheres containing PKC412 inhibits choroidal neovascularization in a porcine model. *Invest. Ophthalmol. Vis. Sci.* (2003) **44**(11):4989-4993.
65. KATO A, KIMURA H, OKABE K *et al.*: Feasibility of drug delivery to the posterior pole of the rabbit eye with an episcleral implant. *Invest. Ophthalmol. Vis. Sci.* (2004) **45**(1):238-244.
66. LAFRANCO DAFFLON M, TRAN VT, GUEX-CROSIER Y, HERBORT CP: Posterior sub-Tenon's steroid injections for the treatment of posterior ocular inflammation: indications, efficacy and side effects. *Graefes Arch. Clin. Exp. Ophthalmol.* (1999) **237**(4):289-295.
67. VENKATESH P, GARG SP, VERMA L, LAKSHMAIAH NC, TEWARI HK: Posterior subtenon injection of corticosteroids using polytetrafluoroethylene (PTFE) intravenous cannula. *Clin. Exp. Ophthalmol.* (2002) **30**(1):55-57.
68. TANNER V, KANSKI JJ, FRITH PA: Posterior sub-Tenon's triamcinolone

- injections in the treatment of uveitis. *Eye* (1998) **12**( Pt 4):679-685.
69. THACH AB, DUGEL PU, FLINDALL RJ, SIPPERLEY JO, SNEED SR: A comparison of retrobulbar versus sub-Tenon's corticosteroid therapy for cystoid macular edema refractory to topical medications. *Ophthalmology* (1997) **104**(12):2003-2008.
  70. AYALASOMAYAJULA SP, KOMPELLA UB: Subconjunctivally administered celecoxib-PLGA microparticles sustain retinal drug levels and alleviate diabetes - induced retinal oxidative stress. *Proceedings of the association for research in vision and ophthalmology annual meeting*. Ft. Lauderdale, Florida, USA (2004) Poster #3957/B418.
  71. KIM H, ROBINSON MR, LIZAK MJ *et al.*: Controlled drug release from an ocular implant: an evaluation using dynamic three-dimensional magnetic resonance imaging. *Invest. Ophthalmol. Vis. Sci.* (2004) **45**(8):2722-2731.
  72. LEE VHL, YAMAMOTO A, KOMPELLA UB: Mucosal penetration enhancers for facilitation of peptide and protein drug absorption. *CRC Crit. Rev. Drug Carrier Sys.* (1991) **8**:191-192.

# Affiliation

Swita Raghava<sup>1</sup>, Makena Hammond<sup>1,3</sup> & Uday B Kompella<sup>†1,2,3</sup>

<sup>†</sup>Author for correspondence

<sup>1</sup>Department of Pharmaceutical Sciences and

<sup>2</sup>Department of Ophthalmology, University of Nebraska Medical Centre, Omaha,

NE 68198-5840, USA

Tel: +1 402 559 5320; Fax: +1 402 559 5368;

<sup>†</sup>E-mail: ukompell@unmc.edu

<sup>3</sup>School of Engineering, Science, and Technology, Virginia State University, USA Petersburg, Virginia, USA